

Early Detection of Diabetic Retinopathy Edema using FCM

Anitha Mohan¹, K. Moorthy²

¹PG Scholar, Department of CSE, Maharaja Prithvi Engineering College
Avinashi, Tamilnadu, India

²Asst.Professor, Department of CSE, Maharaja Prithvi Engineering College
Avinashi, Tamilnadu, India

Abstract: *Diabetic retinopathy (DR) is a common retinal complication associated with diabetes. It is a major cause of blindness in middle as well as older age groups. Therefore early detection through regular screening and timely intervention will be highly beneficial in effectively controlling the progress of the disease. Since the ratio of people afflicted with the disease to the number of eye specialist who can screen these patients is very high, there is a need of automated diagnostic system for diabetic retinopathy changes in the eye so that only diseased persons can be referred to the specialist for further intervention and treatment. The aim of the project is to find the exudates parts in the eye of diabetic patients. In this method, FCM (fuzzy c-means) algorithm is used for finding the ratio of the disease. A major advantage of our algorithm is which implies greater accuracy of exudates detection.*

Keywords: Diabetic macular edema, hard exudates, fuzzy c-means, hue saturation value.

1. Introduction

Diabetic retinopathy (DR), the major cause of poor vision, is an eye disease that is associated with long-standing diabetes. If the disease is detected in its early stages, treatment can slow down the progression of DR. Color fundus images are used to detect exudates in retinal images. Fig. 1 shows a fundus image of an unhealthy retina with its main features and exudates. Once detected during retinal examination, it demands immediate treatment ranging from glycemic and blood pressure control, to laser surgery.

Manual detection of exudates by ophthalmologists is laborious as they have to spend a great deal of time in the analysis and diagnosis of retinal photographs. Automated screening techniques for exudates detection have great significance in saving cost, time and labour. Image processing techniques for exudates detection can help in extracting the location and size of exudates in the retinal images. In color fundus images they appear as yellow-white deposits (see Fig. 1). Detecting the presence of hard exudates (HE) in different areas of retina is now considered a standard method to assess DME from color fundus images.

Several techniques for exudates detection have been proposed. In this method, FCM (fuzzy c-means) algorithm is used for finding the ratio of the disease. The severity of the risk of edema is evaluated based on the proximity of HE to the macula, which is defined to be a circular region centered at fovea and with one optic disc (OD) diameter (see Fig. 1).

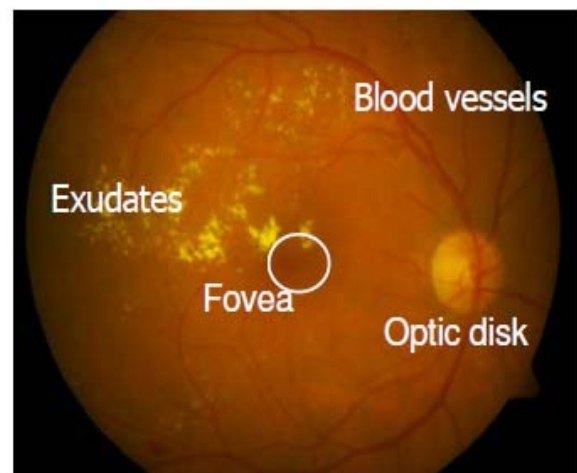


Figure 1: Retinal image with the main features and exudates

In automatic disease detection system can significantly reduce the load of experts by limiting the referrals to those cases that require immediate attention. The reduction in time and effort will be significant where a majority of patients screened for diseases turn out to be normal.

In order to develop a solution for automatic DME assessment, first a decision module is required to validate the presence or absence of HE in a given color fundus image. Once their presence is identified, a second module has to assess the macular region for measuring the risk of exhibiting DME. Therefore, in this work, we propose an accurate method for detection and assessment of DME. The next section provides an overview of the earlier work carried out for detecting the presence of HE followed by an outline of the proposed methodology.

2. Existing System

Set HE appears as clusters of bright, high contrast lesions and are usually well localized. The macula is a dark structure roughly at the center of the retina. In the absence of any HE,

there is a rough rotational symmetry about the macula in the circular region of roughly twice the diameter of the optic disc. We use this observation to derive relevant features to describe the normal and abnormal cases. Given a color fundus image, a circular region of interest (ROI) is first extracted and an intermediate representation also known as the *motion pattern* of the ROI is created. Relevant features are then derived to classify the given image as normal or abnormal.

2.1. Region of Interest Extraction

The severity of DME is determined based on the location of HE clusters relative to the macula, the images acquired for DME detection usually focuses around the macular region. We find the best fit circle within the fundus mask with macula at the center, for a given image. The region within this circle is the desired ROI. The center of macula is automatically detected and restricting the search to a central region of the given image since the acquired images for DME detection are macula-centric.

2.2. Generation of Motion Patterns

The creation of a motion pattern is motivated by the effect of motion on biological/computer visual system. These systems represent a scene as a set of spatially sampled intensities or an image. This sampling is uniform in cameras while it is log polar in human eyes. When an object in a scene moves at a high speed, it usually leaves a smearing pattern in the captured image. Generally, the spatio-temporal changes recorded by the sensor are characteristic of the moving object [30]. In computer vision, the estimation and removal of the smear pattern, also popularly known as motion blur in images, has been an active area of research [31]. We argue that there is much information about the scene in the smear pattern and propose to use it to represent an image. We do this by simulating this operation in a single image by inducing motion.

2.3. Abnormality Detection—Learning Normal Class

Learning normal cases is achieved using *single class classification*. In this approach, a classification boundary is formed in the feature space around the subspace corresponding to normal cases. If a new image, when transformed to this feature space, lies within this boundary, then it is classified as normal and abnormal otherwise. Two simple single class classifiers are considered in this work: Gaussian data description (Gaussian DD) and principal component analysis data description (PCA DD).

2.4. Determining the Severity of Macular Edema

Assessing the severity of macular edema is the next step. Here, the macular region which is the circular ROI within 1 optic disc diameter from the center is of key interest as any HE within this region indicates high risk for DME, requiring intermediate attention. The macula in a normal image is relatively darker than other regions in the fundus image and is characterized by rotational symmetry. We use this

symmetry information to establish the risk of exhibiting edema: good degree of symmetry is taken to indicate the abnormality is not inside macula and hence it is declared as a moderate case. Asymmetry of the macula on the other hand implies abnormality is within the macula and hence the case is deemed severe. A method to detect severity of edema based on rotation symmetry has also been used earlier where the symmetry of larger ROI centered on the macula is considered.

3. Proposed Method

In our proposed method, first step we reduce the noise by using median filter. In median filter reduce the irregular edges or smoothing the edges. After we find the cache in that image then we obtain hue saturation value of the given input image. We are applying FCM (fuzzy c-means) algorithm for finding the ratio of the disease. A major advantage of our algorithm is which implies greater accuracy of exudates detection.

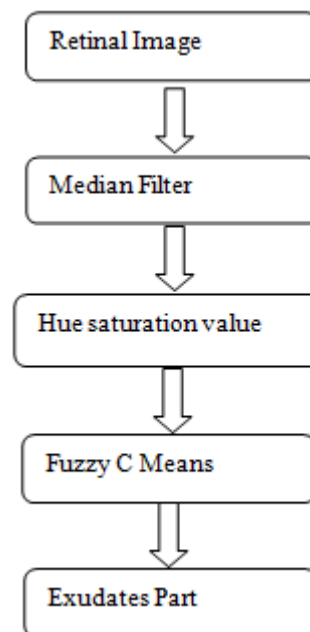


Figure 2: A block diagram outlining the proposed method steps

3.1. Median Filter

The median filter is normally used to reduce noise in an image. The median filter considers each pixel in the image in turn and looks at its nearby neighbors to decide whether or not it is representative of its surroundings. Instead of simply replacing the pixel value with the *mean* of neighboring pixel values, it replaces it with the *median* of those values. The median is calculated by first sorting all the pixel values from the surrounding neighborhood into numerical order and then replacing the pixel being considered with the middle pixel value.

Median filtering is a nonlinear process useful in reducing impulsive or salt-and-pepper noise. It is also useful in preserving edges in an image while reducing random noise. Impulsive or salt-and pepper noise can occur due to a random bit error in a communication channel. In a median filter, a window slides along the image, and the median

intensity value of the pixels within the window becomes the output intensity of the pixel being processed.

3.2. Hue Saturation Value

In the second stage, the given input image is converted to HSV image. Hue is described with the words we normally think of as describing color: red, purple, blue, etc. Hue is more specifically described by the dominant wavelength in models such as the CIE system. Hue is also a term which describes a dimension of color we readily experience when we look at color. It will be the first of three dimensions we use to describe color. Also perceive color changing along two other dimensions. One of the dimensions is lightness-darkness. How light or dark a color is referred to either as a color's lightness or value. In terms of a spectral definition of color, value describes the overall intensity or strength of the light. The last dimension of color that describes our response to color is saturation. Saturation refers to the dominance of hue in the color. These three dimensions of color: hue, saturation, and value constitute a color model that describes how humans naturally respond to and describe color: the HSV model. Because the HSV model has three dimensions, it describes a solid volume. HSV image help us to extract the accurate region.

3.3 .Fuzzy C-Means

Clustering of data is a method by which large sets of data are grouped into clusters of similar sets of similar data. Fuzzy c-means (FCM) is a method of clustering which allows one piece of data to belong to two or more clusters. This method is frequently used in pattern recognition. It is based on minimization of the following objective function:

$$J_m = \sum_{i=1}^n \sum_{j=1}^c u_{ij}^m \|x_i - c_j\|^m, \quad 1 \leq m < \infty \quad (1)$$

where m is any real number greater than 1, u_{ij} is the degree of membership of x_i in the cluster j , x_i is the i th of d -dimensional measured data, c_j is the d -dimension center of the cluster, and $\|*\|$ is any norm expressing the similarity between any measured data and the center.

Fuzzy partitioning is carried out through an iterative optimization of the objective function shown above, with the update of membership u_{ij} and the cluster centers c_j by:

$$u_{ij} = \frac{1}{\sum_{k=1}^c \left(\frac{\|x_i - c_j\|}{\|x_i - c_k\|} \right)^{\frac{2}{m-1}}}, \quad c_j = \frac{\sum_{i=1}^n u_{ij}^m \cdot x_i}{\sum_{i=1}^n u_{ij}^m} \quad (2)$$

4. Conclusion

This project is proposed and evaluated a method for DME detection using FCM method. The color retinal images were segmented using fuzzy C-means clustering following some key preprocessing steps. To classify the segmented regions into exudates and non-exudates, an artificial neural network classifier was investigated. To classify the segmented regions into exudates and non-exudates, an artificial neural network classifier was investigated. This study indicates that automated evaluation of digital retinal images could be used to screen for exudative diabetic retinopathy. The significant contributions of this work are: 1) using median filter to reduce the irregular edges or smoothing the edges. 2) Obtain hue saturation value of the given input image and 3) applying FCM (fuzzy c-means) algorithm for finding the ratio of the disease. A major advantage of our algorithm is which implies greater accuracy of exudates detection. This work can be extended to develop similar diagnostic tools for other ocular diseases and combining it with telemedicine application, for remote, inaccessible and rural areas may prove to be of significant benefit to diagnose various retinal diseases. It is hoped that the developed automatic system could aid the ophthalmologists to detect diabetic maculopathy in early stage and its severity level in less time, also to improve the vision quality of life.

References

- [1] K. Sai Deepak* and Jayanthi Sivaswamy, "Automatic Assessment of Macular Edema from Color Retinal Images"
- [2] L. Giancardo, F. Meriaudeau, T. P. Karnowski, Y. Li, K. W. Tobin, Jr., and E. Chaum, "Automatic retina exudates segmentation without a manually labelled training set," in Proc. 2011 IEEE Int. Symp. Biomed. Imag: From Nano to Macro, Mar. 2011, pp. 1396–1400
- [3] L. Giancardo, F. Meriaudeau, T. Karnowski, K. Tobin, E. Grisan, P. Favaro, A. Ruggeri, and E. Chaum, "Textureless macula swelling detection with multiple retinal fundus images," IEEE Trans Biomed. Eng., vol. 58, no. 3, pp. 795–799, Mar. 2011.
- [4] J. Davidson, T. Ciulla, J. McGill, K. Kles, and P. Anderson, "How the diabetic eye loses vision," Endocrine, vol. 32, pp. 107–116, Nov. 2007
- [5] C. P. Wilkinson, F. L. Ferris, R. E. Klein, P. P. Lee, C. D. Agardh, M. Davis, D. Dills, A. Kampik, R. Pararajasegaram, and J. T. Verdager, "Proposed international clinical diabetic retinopathy and diabetic macular edema disease severity scales," Am. Acad. Ophthalmol., vol. 110, no. 9, pp. 1677–1682, Sep. 2003.
- [6] R. F. N. Silberman, K. Ahlrich, and L. Subramanian, "Case for automated detection of diabetic retinopathy," Proc. AAAI Artif. Intell. Development (AI-D'10), pp. 85–90, Mar. 2010.
- [7] H. Jaafar, A. Nandi, and W. Al-Nuaimy, "Detection of exudates in retinal images using a pure splitting technique," in Proc. Annu. Int. Conf. IEEE Eng. Med. Biol. Soc. (EMBC), Aug. 2010, pp. 6745–6748.
- [8] P. C. Siddalingaswamy and K. G. Prabhu, "Automatic grading of diabetic maculopathy severity levels," in Int. Conf. Syst. Med. Biol. ICSMB), Dec. 2010, pp. 331–334.

- [9] C. I. Sanchez, M. Garca, A. Mayo, M. I. Lopez, and R. Hornero, "Retinal image analysis based on mixture models to detect hard exudates," *Med. Image Anal.*, vol. 13, no. 4, pp. 650–658, Aug. 2009.
- [10] A. Osareh, M. Mirmehdi, B. Thomas, and R. Markham, "Automated identification of diabetic retinal exudates in digital colour images," *Br. J. Ophthalmol.*, vol. 87, pp. 1220–1223, Oct. 2003.
- [11] T. Walter, J.-C. Klein, P. Massin, and A. Erginay, "A contribution of image processing to the diagnosis of diabetic retinopathy-detection of exudates in color fundus images of the human retina," *IEEE Trans. Med. Imag.*, vol. 21, no. 10, pp. 1236–1243, Oct. 2002.
- [12] H. Wang, W. Hsu, K. G. Goh, and M. L. Lee, "An effective approach to detect lesions in color retinal images," in *Proc. IEEE Conf. Comput. Vis. Pattern Recognit.*, 2000, vol. 2, pp. 181–186
- [13]
- [14] M. Garcia, R. Hornero, C. Sanchez, M. Lopez, and A. Diez, "Feature extraction and selection for the automatic detection of hard exudates in retinal images," in *Proc. 29th Annu. Int. Conf. IEEE Eng. Med. Biol. Soc.*, Aug. 2007, pp. 4969–4972.
- [15] K. Ram and J. Sivaswamy, "Multi-space clustering for segmentation of exudates in retinal color photographs," in *Proc. Annu. Int. Conf. IEEE Eng. Med. Biol. Soc.*, Sep. 2009, pp. 1437–1440
- [16] W. Huan, H. Wynne, and L. M. Li, "Effective detection of retinal ex-udates in fundus images," in *Proc. 2nd Int. Conf. Biomed. Eng. In-format.*, Oct. 2009, pp. 1–5.
- [17] J. Singh, G. D. Joshi, and J. Sivaswamy, "Appearance-based object detection in colour retinal images," in *Proc. Int. Conf. Image Process.*, 2008, pp. 1432–1435.
- [18] G. D. Joshi, J. Sivaswamy, K. Karan, and S. R. Krishnadas, "Optic disk and cup boundary detection using regional information," in *Proc. Int. Conf. Image Process.*, 2010, pp. 948–951.
- [19] MESSIDOR, Jun. 2011 [Online]. Available: <http://messidor.crihan.fr/index-en.php>
- [20] DIARETDB0, DIARETDB0: Evaluation database and methodology for diabetic retinopathy algorithms May 2007 [Online]. Available: <http://www2.it.lut.fi/project/imageret/diaretdb0/>
- [21] DIARETDB1, May 2009, DiaRetDB1: Diabetic retinopathy database and evaluation protocol [Online]. Available: <http://www2.it.lut.fi/project/imageret/diaretdb1/>

Author Profile



Anitha Mohan received the B.Tech degree in Computer Science and Engineering from Mahathma Gandhi University in 2007. Currently she is doing M. E at Anna University Chennai in Computer Science and Engineering. As Part of M E Project doing the

Application for the detection of macular edema.